

**Original Article****Complications and Management of Rhinoplasty:  
Our Experience in Bangladesh****Islam MS<sup>1</sup>, Siddiky SA<sup>2</sup>****Abstract:**

**Background:** Rhinoplasty can be either reconstructive or aesthetic. The history of rhinoplasty dates back to 2500 years. It was first documented in the Indian subcontinent by Sushruta, a case of reconstructive rhinoplasty on 600 BC, whereas John Orlando Roe performed the first cosmetic rhinoplasty in 1887 in New York<sup>1</sup>. In the West, rhinoplasty is a very commonly performed operation, but it has not gained popularity in Bangladesh yet. This study was carried out to assess the outcome in our cases of rhinoplasty, specially with regard to complication and their management.

**Methods:** The period of study was from January 2000 to November 2018. 457 cases of rhinoplasty were done. The desires and expectation of the patients were noted; and probable results were discussed before surgery. The procedure for augmentation rhinoplasty consisted of reconstruction of dorsum of the nose by conchal cartilage graft taken from external ear, ulnar bone graft, or silicone (nasal) implant. Other cosmetic rhinoplasty procedures included dorsal hump reduction, tip plasty for bifid or broad tip and Alar Base Reduction for wide nose with alar prominence. Combination procedures were done frequently. Reconstructive rhinoplasty was performed with median/paramedian forehead flap or composite auricular graft.

**Results:** Excellent results were found in 409 cases, satisfactory in 39 cases and unsatisfactory in 09 cases. Complications were minimal and insignificant.

**Conclusion:** We conclude that if expertise is developed rhinoplasty, whether cosmetic or reconstructive, can be performed more frequently and with more satisfactory results. Hands on training, workshops and initial supervision is very important.

**Correspondence to:**

1. Dr. Muhammed Shariful Islam, FCPS, Plastic & Aesthetic Surgeon, Shahid Ziaur Rahman Medical College, Bogura, Cell: 01712002891, Email : abrarwadi@gmail.com

2. Professor Sayeed Ahmed Siddiky, FCPS, FRCS, Consultant, Plastic & Aesthetic Surgeon  
Cosmetic Surgery Centre Ltd. 72 Satmasjid road, Dhanmondi, Dhaka.

**Introduction:**

Rhinoplasty can be either reconstructive or aesthetic. The history of rhinoplasty dates back to 2500 years. It was first documented in the Indian subcontinent by Sushruta, a case of reconstructive rhinoplasty on 600 BC, whereas John Orlando Roe performed the first cosmetic rhinoplasty in 1887 in New York<sup>1</sup>. In the West,

rhinoplasty is a very commonly performed operation, but it has not gained popularity yet in Bangladesh. The reason being lack of adequate number of plastic surgery centers in our country and more importantly the lack of expertise. There is also lack of knowledge about this wonderful operation on the part of the general public. The practicing doctors throughout the country also seem to know very little in this regard.

### Objective:

In western centers rhinoplasty is a very commonly performed operation but it has not yet gained popularity in Bangladesh. This is due to lack of adequate numbers of rhinoplasty surgeons in our country. This study was carried out to assess the outcome in our cases of rhinoplasty, especially with regard to complication and their management.

### Patients & methods :

The period of study is from January 2000 to November 2018. 457 cases of rhinoplasty were done, 431 (94.31%) being cosmetic and 26 (5.6%) reconstructive. Out of 457 cases 361 (79%) were females and 96 (21%) were males. Detailed history was taken and local examination done in all the cases. The desires and expectation of the patients were noted; and probable results were discussed before surgery. The procedure for augmentation rhinoplasty consisted of reconstruction of dorsum of the nose by conchal cartilage graft taken from external ear, ulnar bone graft, or silicone (nasal) implant. Other cosmetic rhinoplasty procedures included dorsal hump reduction,

tip plasty for bifid or broad tip and Alar Base Reduction for wide nose with alar prominence. Combination procedures were done frequently. Reconstructive rhinoplasty was performed with median/paramedian forehead flap or composite auricular graft.

### Results:

457 cases of rhinoplasty were done, 431 (94.31%) being cosmetic and 26 (5.6%) reconstructive. Out of 457 cases 361 (79%) were females and 96 (21%) were males. Excellent results were found in 409 cases, satisfactory in 39 cases and unsatisfactory in 09 cases. Complications were minimal and insignificant.

Table I. Types and sex distribution

Indication	Male	Female	Total
Cosmetic	89	342	431
Reconstructive	07	19	26
Total	96	361	457

Table II. Indications for Rhinoplasty

Indication	No.	%
Cosmetic Rhinoplasty		
Depressed Nose	152	39.82
Dorsal Hump	105	22.97
Bifid Tip	82	17.94
Alar Deformities	54	11.81
Combination	38	8.31
Reconstructive Rhinoplasty		
Human Bites	10	2.18
Accident	8	1.7
Basal Cell Carcinoma	8	1.7

Table III. Types of procedure done

Indication	No.	%
Cosmetic Rhinoplasty		
Augmentation Rhinoplasty	150	32.8
Reduction Rhinoplasty	109	23.9
Tip-plasty	82	18.0
Alar-base	55	11.9
Combination	34	7.4
Reconstructive Rhinoplasty	27	6.0
Total	457	100.00

Table IV. Results

Outcome	Number	%
Excellent	409	89.49
Satisfactory	39	9.41
Unsatisfactory	09	1.10

Table V. Complications

Complication	No.
Bleeding/Hematoma	0
Infection	Nil
Nasal Obstruction	Nil
Cartilage/Implant Displacement	6
Implant extrusion	1
Implant prominence	3
Cartilage Resorption	
Total	10

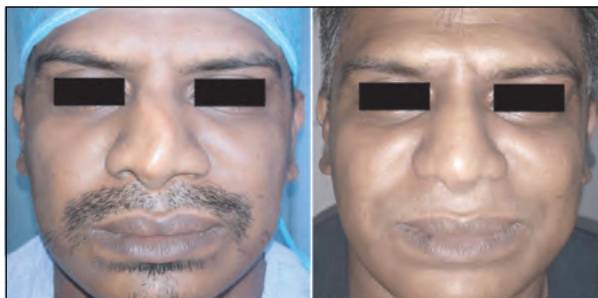

Fig 1 : Warping of rib cartilage; before and after revision rhinoplasty using silicone implant replacement.




Fig 2 : Warped and fractured rib cartilages; removed (left) silicone implant used for replacement (right picture)

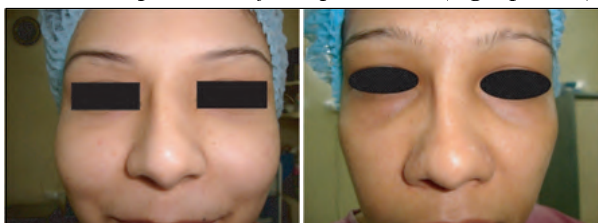

Fig 3: Implant deviation Fig 4: Implant deviation

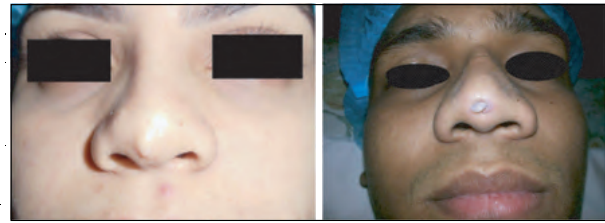


Fig 5 : Impending extrusion Fig 6 : Implant extrusion

**Discussion :**

The fact that rhinoplasty is not a commonly performed operation in our country does not mean there is lack of patients who need this surgery. We believe that there are lots of patients who need rhinoplasty due to various indications. With an experience of 457 cases (from January 2000 to November 2018) we have learned that these patients and their attendants believed that rhinoplasty is not possible in Bangladesh. In fact five of these patients were prepared to go abroad for their treatment. We therefore believe that the general people as well as practicing doctors should be made aware of these types of cosmetic surgeries being carried out in our country, it will enhance referral of patients and alleviate patient's suffering. We had the opportunity to discuss the outcome of rhinoplasty with surgeons who have tried this operation once or twice, but have not continued to practice this surgery due to unrewarding results. It is obvious that no one should not start practicing a new surgery on patients without appropriate training and supervision. We think that rhinoplasty is not an extremely difficult operation, as compared to many of the other surgeries being carried out throughout the country.

There has been a gradual shift from the use of silicon implant to autogenous cartilage and bone graft in augmentation rhinoplasty. Most recent and advanced procedure is use of microdiced conchal cartilage. Conchal cartilages are sliced into micro particles less than 0.5 mm and then wrapped with fascia lata, temporal fascia or periosteum. Patient selection and proper counseling is of utmost importance. Surgeons should be confident in dealing with complications; and have a low threshold for performing revision rhinoplasty whenever required. This can drastically reduce the number of unhappy patients after rhinoplasty.

The bottleneck is an inadequate training facility and minimal supervision for surgeons intending to venture into rhinoplasty procedure. We can develop a centre of excellence where plastic surgeons and ENT surgeons can work together to attain this goal. Interested surgeons can be brought together in groups during intensive training programmes that will include basic anatomy, cadaver dissection and live demonstration of surgical procedures.

Regarding cosmetic rhinoplasty we have started performing augmentation by using conchal cartilage graft. We also used silicone implants that are available as nasal implants or blocks. Bone graft was also used in one case. The other options are outer table of the skull, the olecranon, rib and bovine cartilage<sup>6</sup>.

There are advantages and disadvantages in the closed as well as open rhinoplasty. We have preferred open rhinoplasty in most of our cases. The reason being good exposure

and easy handling of the graft/implant. Of course a single marginal incision inside one of the nostrils is enough to carry out simple procedures like reduction of dorsal hump. When osteotomies are required (during reduction rhinoplasty) an additional marginal incision on the opposite side is required. (In fact there are plastic surgeons who can perform most of these procedures by closed method). Uniting the marginal incision in the midline inferiorly converts the closed to an open method, which provides the surgeon with excellent exposure.

The problem of cartilage resorption and recurrence of deformity can be frustrating for the patient and surgeon alike. We have avoided this complication by taking the cartilage graft along with its perichondrium. This helps the cartilage to remain in shape. This problem can also be overcome by using silicone implants that is not resorbed or cause any adverse effect in the body<sup>9</sup>. The use of implants also obviates the need to perform another surgery on the patient to harvest cartilage or bone.

**Complication:**

The main complications of implant in the nose are infection, extrusion, deviation, prominence and resorption. In general these complications happen in less than 1%. In our series of 457 cases there were 6 cases of implant displacement. 3 patients complained of prominence and only one patient had implant extrusion. We did not encounter excessive bleeding, infection or nasal obstruction in any patient. The patient with cartilage warping in figure 1 and implant extrusion in figure 6.

They were not operated primarily by us. We did their revision surgeries only. 02 cases dislocated autogenous rib cartilages, 04 cases dislocated implant. Autogenous rib cartilage were only used in primary rhinoplasty. With the adequate technique the risk for resorption and distortion even in long term observation are minimal. Significant data on Augmentation Rhinoplasty with diced cartilage are not available in our study. Since the procedure newly started in our country.

Complications encountered in our long experience were handled as below. Implant deviation were corrected by revision under local anesthesia on office procedure. Since all the patients were routinely counseled about the possibility of post operative implant deviation, they could easily be convinced to undergo simple revision procedure.

Impending implant extrusion also require total removal and replacement by cartilage graft/new implant. Implant removal of extruded implant dose not require any anesthesia.

We take care that patient with implant prominence and deviation should go for extrusion. In case of implant extrusion immediate removal of implant was done.

We believe that by corrective pre-operative evaluation, meticulous surgical dissection can help to avoid major complications of rhinoplasty surgery and by adequate pre and post operative counseling we can drastically reduce the number of unsatisfactory outcome.

Patients are adviced to report early incase of implant deviation or implant extrusion. Non-biological materials are generally stable they do not undergo resorption and are not endangered of resorption. Silicone implants that are now commonly used for nasal dorsal augmentation, has extrusion rates of 1-2%. Injectable fillers can correct small impressions after rhinoplasty and avoid revision rhinoplasty.

Autogenous cartilage is still the transplant material of choice for many surgeons. Because there is almost no chance of infection, extrusion or even displacement. Septal cartilage, conchal cartilage are suitable for dorsal augmentation.

#### **Skin and soft tissue- complication:**

Haematoma, infection, skin necrosis, atrophy, fibrosis, pain and numbness are rare complication. We did not face any of these complications in our series.

#### **Conclusion :**

We conclude that rhinoplasty is not a very difficult procedure. Hands on training workshops and initial supervision is very important. If proper expertise and good centers are developed, this surgery can be performed on a regular basis. Rhinoplasty is not a widely practiced operation in our country. With the availability of artificial nasal implants, the procedure of rhinoplasty has become even simpler. Good result in our experience show that rhinoplasty can become a routine procedure for other surgeons as well.

**Reference :**

1. Stark RB. Rhinoplasty. In: Aesthetic Plastic Surgery, 1<sup>st</sup> ed. Boston: Little Brown & Company; 1978.p.73.
  2. Siddiky SA, et al. Rhinoplasty-Review of seven cases performed at the Plastic Surgery Department of Z. H. Sikder Women's Medical College and Hospital. Orion Med J 2001 Sept; 9(6): 522-8.
  3. Mckinney PO. Nasal tip Cartilage Grafts. Ann Plast Surg 1978; 1: 177.
  4. Diamond H. Rhinoplasty Technique. Surg Clin N Am 1971; 51: 317.
  5. Ulloa-Gregori AO, et al. Use of the Nasal SMAS to reconstruct defects of the tip, alac, collumela, or septum. Plasl Reconslr Surg 1999 Sept; 104: 631.
  6. Pittet B, Montandon D. Nasal reconstruction in children: a review of 29 patients. J Craniofac Surg 1998 Nov; 9(6): 522-8.
  7. Miller PJ, Grinberg D, Wang TD. Midline Cleft Treatment of the Bifid Nose. Arch Facial Plast Surg 1999.Jul-Sep; 1(3): 200-3.
  8. Miller PJ, et al. Arch Facial Plast Surg 1999 July-Sept: 200-3.
  9. Quader F, Siddiky SA. Rhinoplasty - A personal experience of sixty seven cases. Paper presented al the 22nd All Nepal Medical Conference on 4th March 2005, in Kathmandu.
-