

Review Article

Hymenoplasty: More than Aesthetic Gynecology

Sharmin A¹, Humayra ZU², Khan MA³

Summery:

Women pursue hymen reconstruction for various personal and cultural reasons. Patients may seek to restore the native hymen following sexual violence, medical interventions, or other involuntary hymenal injuries to reclaim personal ownership of their bodies. Others wish to reexperience their first penetrative sexual encounter with a partner¹. Certainly the most commonly reported motivation is the restoration of physical virginity to align patients with the premarital expectations of their ethnic and religious backgrounds. The role and need of hymenoplasty is debatable. But that is not true for the revirgination procedure. In revirgination the tightness created cannot be denied to a patient by any law anywhere in the world, and it is the right of every woman to request this. Every married couple is entitled to the feel of vaginal tightness and accompanying intensified sexual pleasure. The concept of deception is not relevant. This operation is done for the patients, and the principle of confidentiality is as old as medicine itself. But factors such as sporting activities and the use of tampons mean that bleeding with first sexual intercourse is not essential². Over and above, the method is consistent, reproducible and repeatable if required. The newly reconstructed hymen is strong enough to sustain daily activities, but at the same time weak enough to get ruptured at the time of sexual penetration³.

Keywords: Female genital cosmetic surgery, Hymenoplasty, revirgination.

1. Dr. Afrina Sharmin, Assistant Professor, Department of Surgery, Z. H. Sikder Womens Medical College Hospital, Dhaka.
2. Dr. Zaman Ummay Humayra Assistant Professor, Department of Surgery, East West Medical College Hospital, Dhaka.
3. Dr. Mustafa Amin Khan, Assistant Professor, Department of Plastic Surgery and Burn, National Medical College Hospital, Dhaka, Bangladesh

Correspondence to: Dr. Afrina Sharmin, Assistant Professor, Department of Surgery, Z. H. Sikder Womens Medical College Hospital. Contact no : 01714008081, Email : afrinarimi@gmail.com

Introduction : Hymenoplasty, or the surgical restoration of the vaginal membrane, is one of the least described vulvovaginal procedures in plastic surgery. A variety of terms have been used to describe the configuration and/or distortion of the hymen: attenuation, clefts, tears and transections, bumps and notches⁴. Few studies on hymenal configuration in non abused adolescent girls have

been performed, including girls with and without experience of consensual vaginal intercourse and use of tampons⁵. Hymenoplasty is required to restore the hymen if torn before marriage. Nowadays hymenoplasty is also requested by some females at their 25th anniversary to be enjoyed as re-virgin. The recent increase in requests for genital examinations in girls who may have been sexually abused has necessitated the Knowledge of detailed anatomy. There is also demand for hymenoplasty. The primary reconstructive goal therefore is the restoration of a narrow membranous introitus at the external opening of the vagina. Several techniques for hymenoplasty have been described^{6,7}. The hymen has no discrete physiologic function in the adult female reproductive system. An understanding of native hymen variation, including the most common annular and crescentic configurations, is prerequisite to any reconstructive efforts. The prevalence of different hymen configurations in adulthood and age-related morphologic changes have not been well described. The primary reconstructive goal therefore is the restoration of a narrow membranous introitus at the external opening of the vagina. Several techniques for hymenoplasty have been described in this review⁸.

Preoperative consideration: A full medical and surgical history precedes a standard pelvic exam. Surgeons may consider bringing a chaperone to the examination room for the duration of the

exam for patient comfort and where medicolegal climate dictates it. The hymen remnants, also termed carunculae myrtiformes, should be examined to be of sufficient size for primary reapproximation. Any masses or lesions to the surrounding soft tissues must be recognized and investigated accordingly. Evaluation is necessary for inflammatory processes, malignancy, bleeding disorders, and unrealistic expectations. Vulvodynia or chronic pain in the area is a relative contraindication as this can be exacerbated by genital surgery. Surgical risks of the procedure include wound dehiscence, infection, scarring, distortion of the external vaginal orifice, and creating overly small introitus leading to obstruction of vaginal outflow and hematocolpos, dyspareunia, and feelings of guilt. Patients should be educated that bleeding may not occur during first coitus in over half of women with unruptured hymen and that hymenoplasty cannot guarantee bleeding⁹.

Surgery:

There are multiple technique to get maximum benefit by hymenoplasty. Procedure is carried out under general anaesthesia but can be performed under local anesthesia as well. After a dose of prophylactic antibiotics is given the patient is placed in a lithotomy position with bilateral hips flexed and legs abducted in stirrups. The perineal area is prepped with 10% betadine solution¹⁰.

Miliana Vojvodic, 2018, mentioned in his study about the technique of hymenoplasty. He followed the procedure of luminal

reduction hymenoplasty where Labia majora and minora are retracted bilaterally . The hymen remnants are identified at the outermost aspect of the vaginal introitus as an annular array of hymenal fragments separated by clefts. Remnants can appear flaccid and should be gently stretched to ascertain their actual length. The epithelialized free edges of each hymen fragment are gently excised along the clefts with scissors or a scalpel, leaving only the tip of the fragments intact. The free margin

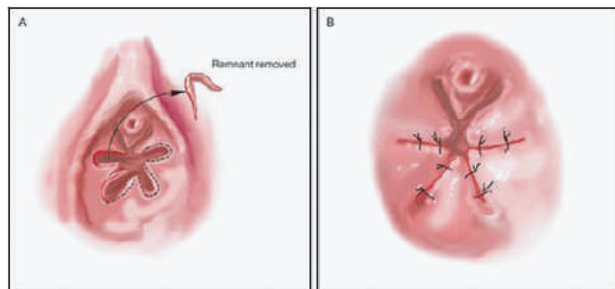


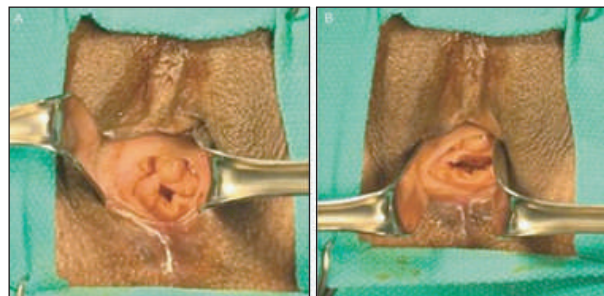
Figure 1: Luminal reduction technique

This is followed by a simple interrupted 4-0 Vicryl rapide suture on the internal surface and another suture on the external surface of the remnants. Sutures are not placed at the anterior aspect of the vaginal canal where the hymen remnants can arise from adjacent to the urethra. All patients are advised to return for follow up on postoperative day one as well as one month and three months following surgery¹⁰ Hemant A. Saraiya, 2015, mention Four vaginal mucosal flaps for reconstruction of a hymen in his research.

Design of flaps around 2.5 cm long and 1 cm wide rectangular flaps are marked at 2, 5, 8 and 11 o'clock position on the anterior vaginal wall. Flaps at 2 and 5 o'clock position are kept proximally based, and flaps at

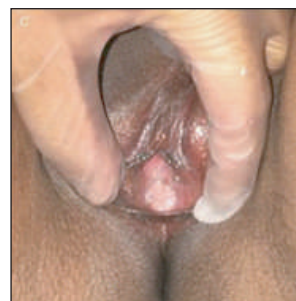

Figure 3,4,5: Luminal reduction technique¹⁰



8 and 11 o'clock positions are kept distally based or vice versa. Flaps are raised at the

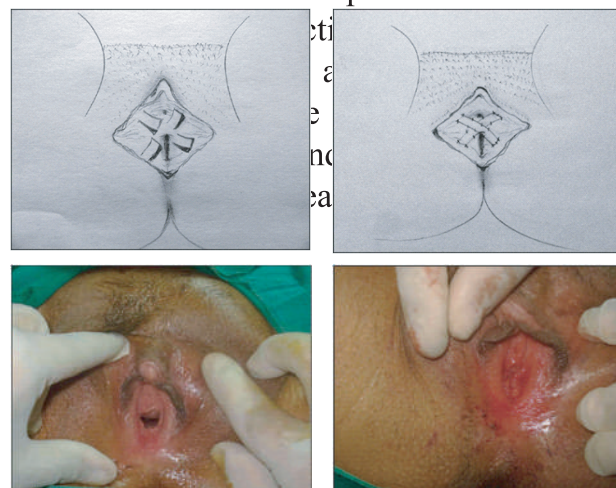


Figure 6,7,8,9: Steps of Four vaginal mucosal flaps¹¹

Discussion:

Abbey B was document the genital anatomy of 211 girls between the ages of 1 month and 7 years who presented for well child care or nongynecologic complaints and who had no history of sexual abuse. Research on the appearance of hymens in prepubertal girls has focused primarily on hymenal configurations and vaginal opening diameters¹¹. Among all 36.0% (76/211) blacks, 33.6% (71/211) white non-Hispanics, 29.9% (63/211) Hispanics, and 0.5% (1/211) Asians. Subjects' ages ranged from 1 to 81 months with a mean of 21 ± 20.6 (SD) months¹¹. Labial agglutination extensive enough to obscure the entire hymen was noted in 10 girls. Three major hymenal configurations were observed: annular, fimbriated, and crescentic. Other configurations noted included a microperforate, sleeve-like hymen with a small opening beneath the urethra in 18 girls and a septated hymen in one subject. Additional features less frequently observed included hymenal tags and bumps. Tags, which were found in 5 subjects. Bumps were distributed around the hymenal edge. Vestibular bands or ligaments in the periurethral area in all 155 girls and 11 of these girls also had bands elsewhere on the hymen. McCann et al noted vestibular erythema, labial adhesions, penurethral bands, midline sparing, and vaginal ridges in many girls without a history of abuse or genital trauma^{10,11}

	Age			
	1-12	13-24	25-48	49-81
Horizontal diameter mm				
No	35	26	27	25
Mean \pm SD	2.5 ± 0.8	2.9 ± 1.2	2.9 ± 1.0	3.6 ± 1.2
Range	01-3.5	1.5-6.5	1.0-6.5	2.0-4.8
Vertical diameter mm				
No	11	8	14	6
Mean \pm SD	3.4 ± 1.4	2.8 ± 1.0	3.6 ± 1.2	3.9 ± 1.7
Range	1.8-6.0	1.0-4.3	1.0-6.0	1.0-8.8
Inferior rim mm				
No	28	26	29	24
Mean \pm SD	2.8 ± 0.8	2.7 ± 1.1	2.7 ± 0.9	2.7 ± 0.7
Range	1.5-4.5	0.9-5.0	0.9-5.0	1.0-3.8

Table 1 : Classification of Hymenal Findings in Prepubertal Girls by Age¹¹

Goff et al examined 273 prepubertal girls during their routine health assessment and determined that an opening greater than 4 mm was rare. Emans et al compared 20 genital findings in three groups of girls: and find labial agglutination extensive enough to obscure the hymen was present in 5% of subjects and partial agglutination was observed in an additional 17%. Newborns have abundant hymenal tissue, which appears folded or redundant. Hymens to those with at least three separations in the rim resulting in a ruffled edge. The fimbriated configuration includes all hymens with persistence of a redundant or fringed nature regardless of whether multiple separations in the rim were

present^{11,12}. The sleeve-like hymen has been described both as an annular hymen with a ventrally displaced orifice in newborns and as a microperforate hymen in older children. Study observed in girls >48 months old with previous investigators have suggested that hymenal bumps and intravaginal ridges may be suggestive of sexual abuse, but this study found that 7% of girls had bumps and 25% intravaginal ridges. These percentages are lower than McCann and coworkers' report of 18% for bumps (knee-chest position) and 90.2% for intravaginal ridges, perhaps because the mean age in this 28 years. Longitudinal intravaginal ridges commonly occur in the newborn and in the young child. Additionally, the intersection of an intravaginal ridge and the rim appeared as a bump in 4% (8/202) of our subjects^{13,14,15}. If a bump is observed, it is important to determine its origin. Patient requests for hymenoplasty should be approached by surgeons with a willingness to understand patients' social contexts and reasons for pursuing the procedure and are ethically justified by leading Islamic jurists in particular circumstances^{11,16}.

Shu-Yi Wei, 2014, describe Overall, 125 patients had undergone hymenoplasty using the STSI method. Only 1 (0.8%) patient had an early postoperative complication (uncontrolled bleeding). Among the 99 patients who returned for followup at 1 month, healing was recorded for 91

(91.9%)^{17,18,29}. Long term followup suggested that no patient had persistent dyspareunia, menstruation changes, or other health problems after the surgery. Among 51 patients who reported sexual intercourse since the surgery, 47 (92.2%) were satisfied with the outcome and 28 (54.9%) reported blood loss during the first intercourse⁸. He suture three stratum around the introitus (STSI) technique described by Wei et al employs suture layers along 3 stratum, the inner and outer hymena mucosa and intervening submucosal fascia^{18,19,20}. There are techniques described by Goodman. This technique is a simple and effective method for hymen reconstruction where sufficient hymen remnants are present²¹.

Bianca R. van, 2012 publish Results eighty-two women were interviewed at first visit. Sixty-eight women were followed until their decision to be operated upon or not. Forty-eight percent of all subjects reported a history of sexual violence, and 37% had had one or more abortion^{22,27,29}.

A total of nine cases have been performed by the senior authors (F.L. and J.A.) between April 2011 and June 2017 and were compiled as a comprehensive and consecutive case series^{23,24}. The average patient age was 26.9 years old (range, 21.8-37.7 years old) with an average BMI of 21.9 kg/m² (range, 18.3-30.0 kg/m²). The average operative time was 23 minutes (range, 10-42 minutes). The average length

of follow up was 64 days (range, 4-146 days) postoperatively^{23,24,26,10}.

Conclusion:

Hymenoplasty is not same as revirgination surgery and patients do not always appreciate the differences. Women requesting hymenoplasty should be offered complete revirgination surgery which includes hymenoplasty, vaginoplasty and bulbospongiosoplasty³¹.

Reference:

1. Longmans A, Verhoeff A. Who wants the procedure and why. *BMJ* 1998;316:459-60.
2. Prakash V. How I do Hymenoplasty. *Indian Journal of Surgery* 2009;71:221-3.
3. Prakash V, Neeta G. New Technique for Management of Relaxed Vagina –Preliminary Study. *Anaplastology* 2014;3:1.
4. Goodman MP. Female Cosmetic Genital Surgery. *Obstetric Gynec* 2009;113:154-9.
5. Kandela P. Egypt's Trade in Hymen Repair. *Lancet* 1996;347:1615.
6. O'Connor M. Reconstructing the hymen: mutilation or restoration. *J Law Med* 2008;16(1):161-75.
7. Ou Mc, Lin C, Ou D. A cercelage method for hymenoplasty. *Taiwan J Obstetric Gynecology* 2008;47(3):355-6.
8. Emans SJ. Hymeneal findings in adolescent women. *J Pediatric* 1994;125:153-60.
9. Hemant A, Saraiya. Surgical revirgination: Four vaginal mucosal flaps for reconstruction of a hymen. *Indian J Plast Surg.* 2015 May-Aug; 48(2): 192–195.
10. Vojvodic M, Lista F, Vastis PG and Ahmad J, Luminal Reduction Hymenoplasty: A Canadian Experience With Hymen Restoration, *Aesthetic Surgery Journal*, 2018l, Vol 38(7) 802–806
11. Saraiya HA. Surgical revirgination: Four vaginal mucosal flaps for reconstruction of a hymen. *Indian J Plast Surg.* 2015;48(2):192-195.
12. Bawany MH, Padela AI. Hymenoplasty and Muslim Patients: Islamic Ethico-Legal Perspectives. *J Sex Med* 2017;14:1003–1010.
13. Vincanne Adams, *Recreating Virginitly in Iran: Hymenoplasty as a Form of Resistance*, *Medical Anthropology Quarterly* branding banner, Vol. 33, Issue 4, December 2019, 221-224
14. Gellhorn G. Anatomy, pathology and development of the hymen. (1904) *Trans. Am. Gynec. Soc., Philadelphia*, 29: 405 - 440.
15. Bianca R. van Moorst, Rik H. W. van Lunsen, *Backgrounds of women applying for hymen reconstruction, the effects of counselling on myths and misunderstandings about virginity, and the results of hymen reconstruction*, Pages 93-105 | Published online: 31 Jan 2012
16. Abbey B. Berenson, MD; Astrid H. Heger, *Appearance of the Hymen in Prepubertal Girls*, *PEDIATRICS* Vol. 89 No. 3 March 1992 ,387-395.
17. Amy JJ. Certificates of virginity and reconstruction of the hymen. *Eur J Contracept Reprod Health Care.* 2008;13(2):111-113.
18. Kandela P. Egypt's trade in hymen repair. *Lancet.* 1996;347(9015):1615.
19. Juth N, Lynøe N. Are there morally relevant differences between hymen restoration and bloodless treatment for Jehovah's Witnesses? *BMC Med Ethics.* 2014;15:89.
20. Cook RJ, Dickens BM. Hymen reconstruction: ethical and legal issues. *Int J Gynaecol Obstet.* 2009;107(3):266-269.
21. Heinrichs G. Is Hymenoplasty Anti-Feminist? *J Clin Ethics.* 2015;26(2):172-175.

22. Ahmadi A. Recreating Virginitly in Iran: Hymenoplasty as a Form of Resistance. *Med Anthropol Q.* 2016;30(2): 222-237.
 - 23.. Raveenthiran V. Surgery of the hymen: from myth to modernisation. *Indian J Surg.* 2009;71(4):224-226. 11. Prakash V. Hymenoplasty - how to do. *Indian J Surg.* 2009;71(4):221-223.
 24. Ou MC, Lin CC, Pang CC, Ou D. A cerclage method for hymenoplasty. *Taiwan J Obstet Gynecol.* 2008;47(3):355-356.
 25. 26. 27. Triana L, Robledo AM. Aesthetic surgery of female external genitalia. *Aesthet Surg J.* 2015;35(2):165-177.
 28. Prakash V , Garg Neeta, Revirgination is not the same as hymenoplasty, www.pmfanews.com, february/march 2016; vol 3 no 3.
 29. Bianca R. van Moorst,Rik H. W. van Lunsen,Dorenda K. E. van Dijken &Concetta M. Salvatore, Backgrounds of women applying for hymen reconstruction, the effects of counselling on myths and misunderstandings about virginitly, and the results of hymen reconstruction, ournal, *The European Journal of Contraception & Reproductive Health Care* , 2012; Vol 17, no 2: 93-105
 30. Logmans A, Ethical dilemma: Should doctors reconstruct the vaginal introitus of adolescent girls to mimic the virginal state? *BMJ* 1998; 316 doi: <https://doi.org/10.1136/bmj.316.7129.459> (Published 07 February 1998)
 31. Goff CW, Burke KR, Rickenback C, Buebendorf DP, Vaginal Opening Measurement in Prepubertal Girls, *Am J Dis Child.* 1989;143(11):1366-1368
-