

Case Report

Resurfacing Large Palmar Hand Wound with an Aesthetic Demand from a Patient: A Case Report

Rahman H¹, Azad MAK², Mannan MA³, Rouf RS⁴

Abstract:

Early, single stage reconstruction of hand wound with a well vascularised tissue carries the best possible result. It also enables to do any secondary procedures for tendon, nerve or joints. Free tissue transfer is only rarely indicated for the palm. when required, however, these procedures can limit hospital stay and overall cost. Commonly used free flap like radial forearm flap, dorsalis pedis flap, MSAP flap, and lateral arm flap can serve the purpose of resurfacing with good functional result, but they do not match the color and texture of the palm. In this article, we have discussed a case of post burn scar contracture of hand where the patient demanded a colour and texture match of palm and denied to do a conventional free flap. So we did a medial plantar free flap to resurface the palmar defect. The results were good in terms of functional gain and very satisfactory in like with like replacement with colour and texture match.

Key words: Free flap, soft tissue defect of hand.

1. Dr. Hasib Rahman, Associate Professor, Plastic Surgery, Dhaka Medical College and Hospital.
2. Dr. Md. Abul Kalam Azad, Associate Professor, Surgery, Mymensing Medical College and Hospital.
3. Dr. M.A. Mannan, Assistant Professor, Surgery, Sylhet MAG Osmani Medical College and Hospital.
4. Dr. Rushda Sarmin Binte Rouf, Registrar, Department of Endocrinology, BIRDEM.

Correspondence to:

Dr. Hasib Rahman, Associate Professor, Plastic Surgery, Dhaka Medical College and Hospital.
Email: dr.hasibrahman@gmail.com; cell phone: 01711-016996.

Introduction: A reconstructive surgeon is often disposed with the task of resurfacing a palmar hand wound. The wound may result from trauma, burn, infection or a surgeon himself may create the wound after excision of tumor or release of contractures. The optimum soft tissue reconstruction provides a durable yet pliable cover which will prevent contracture, underneath which tendons will glide smoothly and allow the hand all forms of power grip and to execute delicate skills. Although palmar aspect of the hand is frequently involved in accidents, full thickness injury with exposed tendon, nerves and vessels are rare. The reason for this is the similarity of palmar skin to that of the glabrous skin of the

sole which is thick, shock absorbing and resistant to mechanical strain¹. There are many local, regional and distal flaps for resurfacing a palmar hand wound. The “reconstructive ladder” described by Mathes and Nahai is based on the principle of using the simplest approach however to cover a wound which will maintain form and optimize function². This approach is not preferable in all case. Skin grafts are never preferable for a palmar wound, local flaps like distally based pedicled radial forearm flap leaves an unacceptable donor deformity and may not be feasible in a complex trauma with vascular injury; Groin or abdominal flaps are bulky and requires prolonged hospital stay and a secondary stage. Development of a wide spectrum of free flaps (radial forearm, lateral arm, MSAP, dorsalis pedis free flap etc.) over the years have enriched the armamentarium of a reconstructive surgeon and allows him/her to choose a suitable flap of adequate size and composition depending on the need of the patient. When carried out properly they all carry good results in terms of function but they do not mimic colour and texture match of the palm. In this paper the author will discuss a case of free medial planter flap for palmar hand wound where the patient demanded a color match as well as good functional outcome.

Case report:

A 27 year old male presented with post burn scar contracture of middle, ring and little finger, midpalmar space contracture with ulnar deviation of wrist joint of left hand. After scar excision and contracture release

mid palmar space defect was 9X6cm. A free medial planter flap from left foot was harvested and used to resurface the defect.

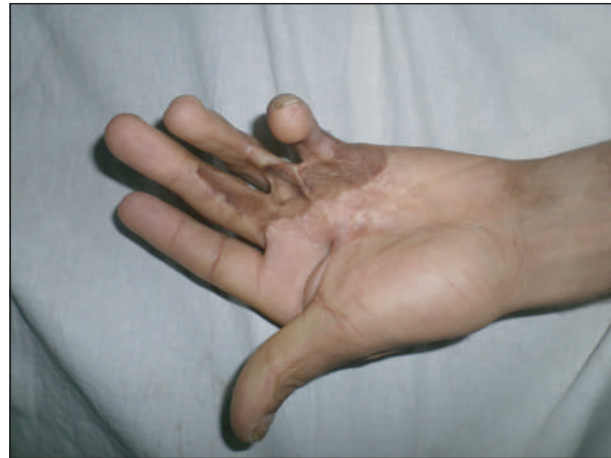

Fig 1(a): PBSC left hand

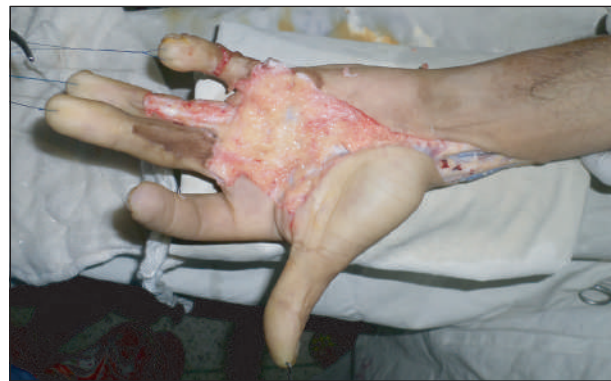

Fig 1 (b): Wound after release of contracture

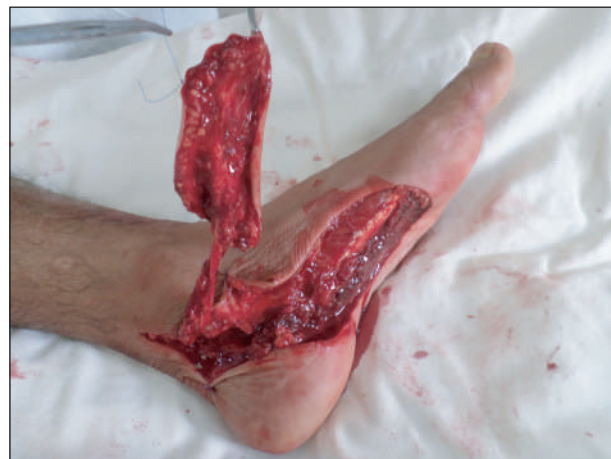

Fig 1 (c): Medial planter flap harvested

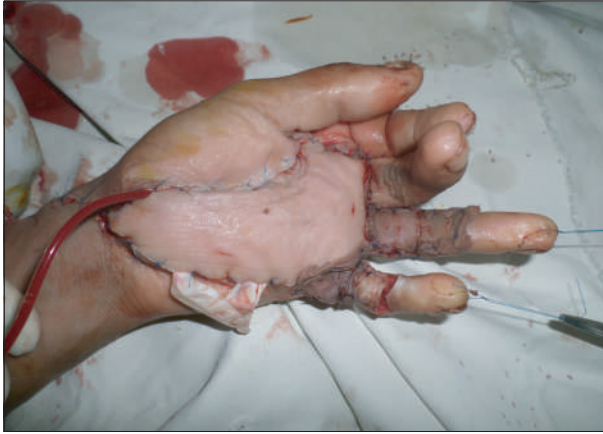

Fig 1 (d): Flap inset

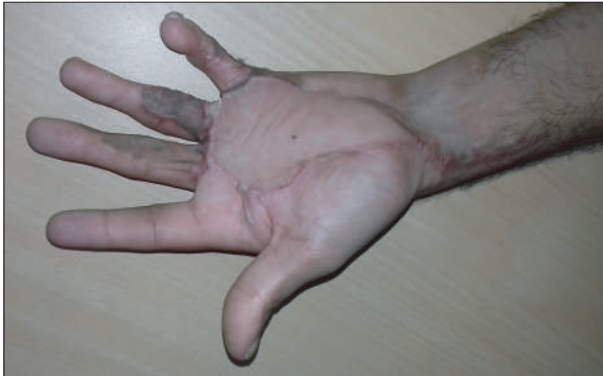
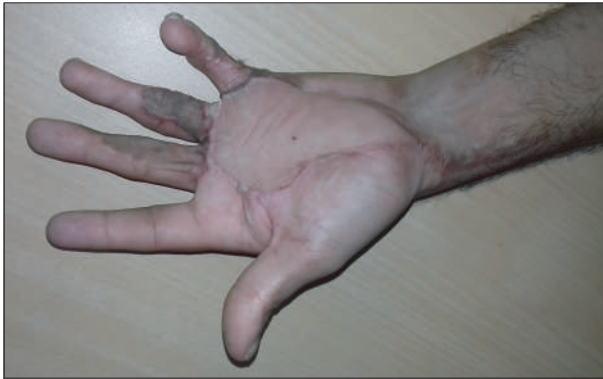
Fig 1 (e) and (f): Satisfactory finger extension, opposition and flexion after 13 months

Vascular anastomoses were performed between medial plantar vessels with radial artery and venae comitantes and cephalic vein in end to end fashion. Donor site was skin grafted.

Results: In terms of function patient had good recovery of finger flexion, opposition and grip strength. Aesthetic results were very satisfactory as flap color mimicked the colour as well as glabrous nature of the native skin. Flap was thin and pliable. Patient was very satisfied with result.

Discussion: There are limited indications for free flap cover of a palmar defect. Local or regional flaps like reverse radial forearm flap, posterior interosseous flap, groin or abdominal flap can be used to cover most of the defects. However many surgeons prefer for free tissue transfer to avoid a donor site in as already mutilated hand or forearm^{3,4}. Young women may prefer a flap from inconspicuous donor site to avoid an unsightly scar in forearm^{5,6}. Ultimate decision will depend on size and nature of the defect, vascular status, exposed structures, patient's profile and choice and expertise of the surgeon.

It is very difficult to follow Gillies' concept of 'replace like with like' in palmar defects. Never the less the aim of reconstruction is to have a thin, soft, pliable cover, easily adjusted to contour of hand, allows early mobilization and physiotherapy and most importantly facilitates secondary reconstruction of tendon or nerves when needed⁷.

Common free flaps which are used to cover palmar surface are radial forearm, lateral arm, parascapular, dorsalis pedis, medial plantar, serratus fascial flap and temporoparietal fascia free flap. Choice of the flap is individualized according to the defect and body habitus of the patient.

For example, lateral arm flap which is suitable for one patient may be too thick with subcutaneous fat in another patient. For a thin free flap temporoparietal fascia or serratus anterior fascia flap is ideal for palm. There is no donor site morbidity, scar is not conspicuous and allows secondary procedures after 4-6 months^{8, 9,10}. However they need additional skin graft over the flap and technically more demanding. Cutaneous free flaps are indicated for large and medium sized defect. Commonly used cutaneous free flaps are parascapular free flap¹¹, lateral arm flap¹², contralateral radial forearm flap¹³ and dorsalis pedis flap. Cutaneous flap has the additional advantage of

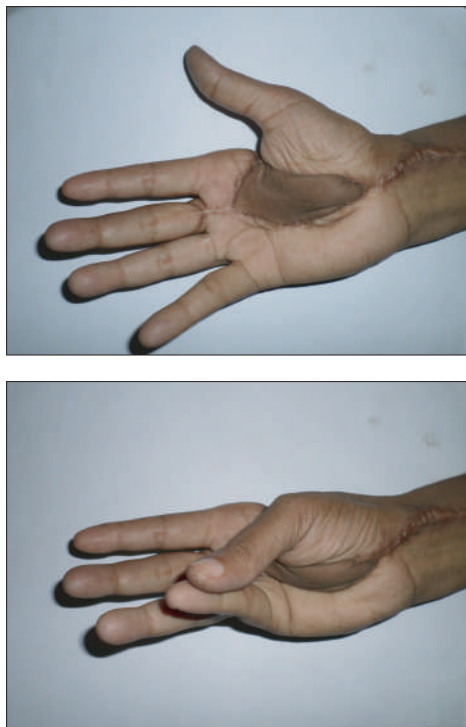


Fig 2 a and b: Compared to free medial plantar flap, dorsalis pedis free flap has similarly good functional result but doesnot have colour and twxture match of palm.

permitting immediate primary steps of later reconstruction, such as placing hunter rods for delayed tendon reconstruction.

The only flap that can replace like with like of palmar skin is medial plantar island flap or instep island flap. Several case reports published excellent results. The flap can be re-innervated and resembles texture of the palm^{14,15}.

In our experience we did four different types of free flaps for palmar defects. They were radial forearm free flap, dorsalis pedis free flap, lateral arm free flap and medial plantar free flap.

In terms of function all carried good results but aesthetic outcome was superior in free medial plantar free flap. It has an additional advantage of a hidden donor area in foot in contrast with a visible donor site in forearm in radial forearm.

Conculation :

Although technically difficult, a free medial plantar flap is a good option for palm resurface in patients who demand a superior aesthetic outcome.

References :

1. Germann G, Sherman R, Levin LS. Decision making in reconstructive surgery. New York: Springer;1999.
2. Janis JE, Kwon RK, Attinger CE. The new reconstructive ladder: modifications to the traditional model. *Plast Reconstr Surg.* 2011;127 (suppl 1):205Se212S.
3. Ninkovic MM, Schwabegger AH, Wechselberger G, Anderl H. Reconstruction of large defects of the hand using free flaps. *J Hand Surg* 1997;22:623-30.

4. Wood MB, Irons GB. Upper-extremity skin flap transfer: results and utility as compared with conventional distant pedicle skin flaps. *Ann Plast Surg* 1983;11:523-6.
 5. Hulsberger KS, Muller K, Partecke BD. Donor site defect after removal of free and pedicled forearm flaps: functional and cosmetic results. *Handchir Mikrochir Plast Chir* 1996;28:70-5.
 6. Upton J, Rogers C, Durham-Smith G, Swartz WM. Clinical application of tempo-parietal flaps in hand reconstruction. *J Hand Surg* 1986;11:475-83.
 7. Millesi H. Forty-two years of peripheral nerve surgery. *Microsurgery* 1993;14(4):228-33.
 8. Brent B, Upton J, Acland RD. Experience with the temporoparietal fascial free flap. *Plast Reconstr Surg* 1985;76: 177-80.
 9. Gordon L, Levinsohn DG, Finkemeier C, Angeles A, Deuth H. The serratus anterior free muscle transplant for reconstruction of the injured hand: an analysis of the donor and recipient sites. *Plast Reconstr Surg* 1993;92:97-101.
 10. Rose EH, Norris MS. The versatile temporoparietal fascial flap: adaptability to a variety of composite defects. *Plast Reconstr Surg* 1990;85:224-32.
 11. Burns JT, Schaily B. Use of the parascapular flap in hand reconstruction. *J Hand Surg Am* 1986;11:872-81.
 12. Katsaros J, Schusterman M, Beppu M, Banis JC, Acland RC. The lateral upper arm flap: anatomy and clinical applications. *Ann Plast Surg* 1984;12:489-500.
 13. Timmons MJ. The vascular basis of the radial forearm flap. *Plast Reconstr Surg* 1986;77:80-92.
 14. Morrison WA, Crabb DM, O'Brien BM. The instep of the foot as a fasciocutaneous island and as a free flap for heel defects. *Plast Reconstr Surg* 1983;72:56--65.
 15. LeWorthy GW. Sole skin as a donor site replace palmar skin. *Plast Reconstr Surg* 1963;32:30-6.
-